

Anomalous Origin of the Right Coronary Artery from the Left Coronary Sinus with an Interarterial Course: Subtypes and Clinical Importance¹

Hye-Jeong Lee, MD, PhD
Yoo Jin Hong, MD
Hee Yeong Kim, MD
Jiwon Lee, MD
Jin Hur, MD, PhD
Byoung Wook Choi, MD, PhD
Hyuk-Jae Chang, MD, PhD
Ji Eun Nam, MD
Kyu Ok Choe, MD, PhD
Young Jin Kim, MD, PhD

Purpose:

To classify anomalous origins of the right coronary artery (RCA) from the left coronary sinus (AORL) with an interarterial course into two subtypes and to evaluate the clinical importance of each.

Materials and Methods:

Institutional review board approval was obtained for this retrospective study, and informed consent was waived. Through a retrospective review of 22925 consecutive cardiac computed tomographic (CT) scans, 124 cases of AORL with an interarterial course were identified. These anomalies were classified into two subtypes according to the location of the anomalous RCA ostium: high interarterial course (between the aorta and the pulmonary artery) and low interarterial course (between the aorta and the right ventricular outflow tract). The clinical records were evaluated, and differences in prevalence of typical angina and major adverse cardiac events (MACEs) between the subtypes were analyzed through the χ^2 contingency tables or Fisher exact test.

Results:

After excluding patients with combined cardiac disease, 87 patients (51 [59%] men, 36 [41%] women; mean age, 56.0 years) were enrolled. Of the 87 patients, 53 had a high interarterial course and 34 had a low interarterial course. A significant difference in the prevalence of typical angina (high [43%] vs low [6%], $P = .001$) and MACE (high [28%] vs low [6%], $P = .012$) was observed between the two subtypes. For patients with a high interarterial course, the odds ratio for typical angina was 12.3 (95% confidence interval: 2.7, 56.6), and the odds ratio for MACE was 6.3 (95% confidence interval: 1.3, 29.7).

Conclusion:

The prevalence of typical angina and that of MACE were significantly higher in patients with a high interarterial course than in those with a low interarterial course.

©RSNA, 2011

Supplemental material: <http://radiology.rsna.org/lookup/suppl/doi:10.1148/radiol.11110823/-/DC1>

¹From the Department of Radiology, Research Institute of Radiological Science (H.J.L., Y.J.H., H.Y.K., J.L., J.H., B.W.C., J.E.N., K.O.C., Y.J.K.), and Division of Cardiology, Department of Internal Medicine (H.J.C.), Severance Hospital, Yonsei University Health System, 250 Seongsanno, Seodaemun-gu, Seoul 120-752, Korea. From the 2010 RSNA Annual Meeting. Received April 21, 2011; revision requested May 24; final revision received June 29; accepted July 15; final version accepted August 3. Address correspondence to Y.J.K. (e-mail: dryj@yuhs.ac).

The prevalence of coronary artery anomalies at conventional coronary angiography is approximately 1%. However, a higher incidence of coronary artery anomalies is observed in young victims of sudden death (4%–15%) when compared with adults (1%) (1). Recent reports state an anomalous origin of the right coronary artery (RCA) from the left coronary sinus (AORL), with an interarterial course as the most common coronary anomaly (2,3).

AORL with an interarterial course between the aorta and the pulmonary trunk may be associated with myocardial ischemia and may be the cause of myocardial infarction (MI), sudden cardiac death, arrhythmia, and syncope (4–6). However, experience with this anomaly, which has accumulated with the widespread use of cardiac multidetector computed tomography (CT), has taught us that the presence of the anomaly does not necessarily lead to myocardial ischemia or sudden cardiac death (7). For proper treatment of patients with this anomaly, therefore, a method must be found to differentiate those patients who are at risk for sudden death from those who are not.

The development of electrocardiographically gated multidetector CT allows for the accurate and noninvasive depiction of coronary artery anomalies, and multidetector CT has been shown to be superior to conventional coronary angiography in delineating the origin and

proximal path of anomalous coronary arteries (8,9). However, few studies on clinically significant differences for these coronary artery anomalies have been performed by using multidetector CT (10,11).

We hypothesized that the hemodynamic significance of AORL with an interarterial course differs according to the location of the anomalous RCA ostium, because the hemodynamic significance might depend on the degree of RCA ostium compression and/or the interarterial RCA segment. An RCA ostium located above the pulmonary valve (high interarterial course) would be more compressed, because blood is forced into the aorta and pulmonary artery during systole, resulting in simultaneous distention of these vessels, which in turn may lead to compression of the interarterial segment between these great vessels. This phenomenon can be aggravated during exercise. On the other hand, the right ventricular outflow tract (RVOT) contracts during systole, so an RCA ostium below the pulmonary valve (low interarterial course) would be less compressed between the aorta and RVOT (Fig 1).

Therefore, the purpose of this study was to classify AORL with an interarterial course into high and low subtypes according to the location of the anomalous RCA ostium with multidetector CT and evaluate the clinical importance of each subtype.

We searched our database for radiologic examinations at our institution from January 2005 through July 2010. A total of 22 925 consecutive patients underwent cardiac CT during this period because they were suspected of having coronary artery disease or they were undergoing a health checkup, and we identified 390 patients (1.7%) of 22 925 with coronary artery anomalies. Of these, 124 (31.8%) of 390 had AORL with an interarterial course. The exclusion criteria that were applied to these patients were other combined cardiac diseases that could account for patients' symptoms, such as coronary artery disease, other coronary artery anomalies, myocardial disease, and valvular heart disease.

Pertinent clinical history and all available clinical test data, including results of resting electrocardiography, echocardiography, cardiac stress tests (treadmill test or cardiac nuclear scan with technetium 99m sestamibi), and conventional coronary angiography, were collected for each patient by reviewing electronic medical records. We classified patients according to the characteristics of their chest pain as follows: typical, atypical, nonanginal, and no chest pain. According to American College of

Advances in Knowledge

- The anomalous origin of the right coronary artery (RCA) from the left coronary sinus (AORL) might be divided into two subtypes (high and low) according to the location of the anomalous RCA ostium, and there might be a difference in hemodynamic significance between these subtypes.
- The prevalence of typical angina and major adverse cardiac events was significantly higher in patients with a high interarterial course of AORL than in those with a low interarterial course.

Materials and Methods

Patient Populations

Institutional review board approval was obtained for this retrospective study, and informed consent was waived.

Implications for Patient Care

- This classification may be helpful in treating patients with AORL with an interarterial course in clinical practice.
- Physicians should pay particular attention to patients with a high interarterial course, especially in the younger population.

Published online before print

10.1148/radiol.11110823 Content code: CA

Radiology 2012; 262:101–108

Abbreviations:

AORL = anomalous origin of the RCA from the left coronary sinus

MACE = major adverse cardiac event

MI = myocardial infarction

RCA = right coronary artery

RVOT = right ventricular outflow tract

Author contributions:

Guarantors of integrity of entire study, H.J.L., H.Y.K., J.L., K.O.C., Y.J.K.; study concepts/study design or data acquisition or data analysis/interpretation, all authors; manuscript drafting or manuscript revision for important intellectual content, all authors; approval of final version of submitted manuscript, all authors; literature research, H.J.L., Y.J.H., H.Y.K., J.H., K.O.C., Y.J.K.; clinical studies, H.J.L., H.Y.K., J.L., J.H., B.W.C., H.J.C., J.E.N., K.O.C., Y.J.K.; statistical analysis, H.J.L., H.Y.K., J.H., B.W.C., Y.J.K.; and manuscript editing, H.J.L., Y.J.H., H.Y.K., B.W.C., H.J.C., K.O.C., Y.J.K.

Potential conflicts of interest are listed at the end of this article.

Figure 1

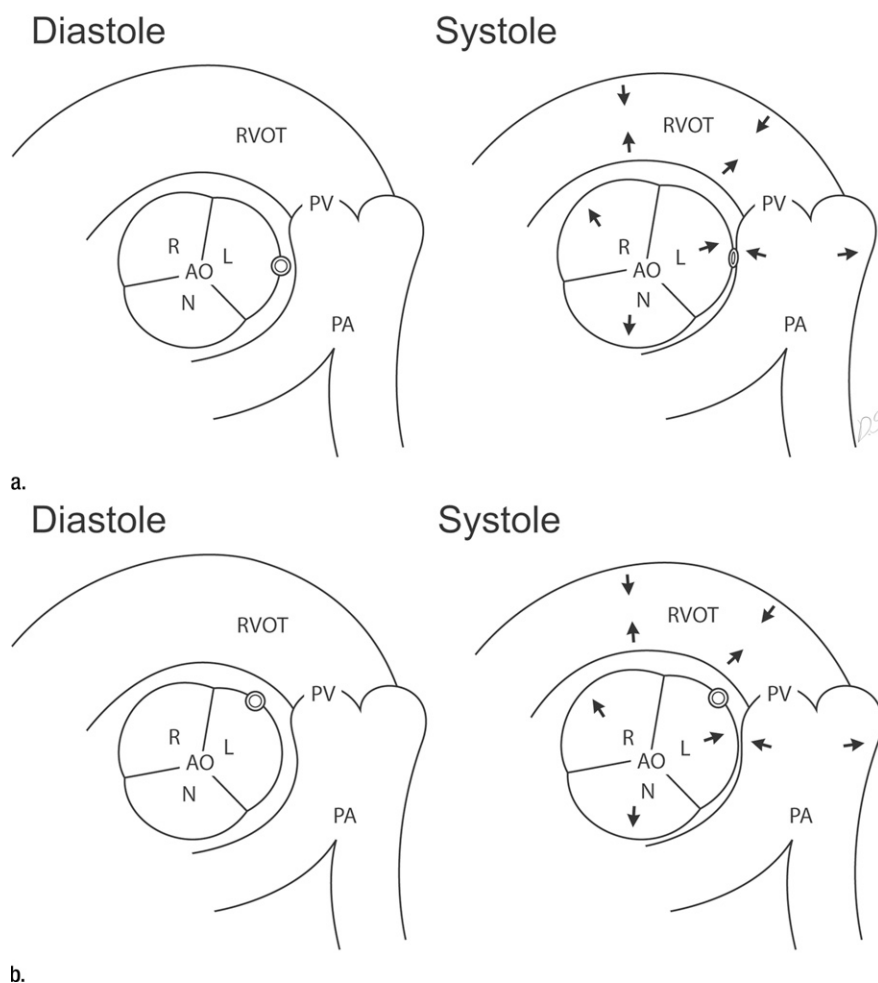


Figure 1: Diagram of subtypes for interarterial course of anomalous RCA from the left coronary sinus (L). **(a)** High interarterial course. An anomalous RCA ostium (double circle, also on both images in **b**) is located between the aorta (AO) and the pulmonary artery (PA). During systole, simultaneous distention of the aorta and the pulmonary artery occurs (shown by direction of arrows on image at right) and the anomalous ostium of high interarterial course (double oval) is compressed between the aorta and the pulmonary artery. **(b)** Low interarterial course. An anomalous RCA ostium is located between the aorta and the RVOT. During systole, the aorta distends but the RVOT contracts (shown by direction of arrows on image at right). So the anomalous RCA ostium would be less compressed than in high interarterial course. N = noncoronary sinus, PV = pulmonary valve, R = right coronary sinus.

Cardiology–American Heart Association guidelines (12), *typical angina* was defined as follows: (a) substernal chest discomfort with a characteristic quality and duration that is (b) provoked by exertion or emotional stress and (c) relieved by rest or nitroglycerin. *Atypical angina* was defined as chest discomfort that lacks one of the above characteristics, and *nonanginal chest pain* was defined as chest discomfort that met one

or none of the typical angina characteristics. We evaluated the presence of other symptoms such as syncope, dyspnea, and palpitation in patients with no chest pain; patients who were asymptomatic were classified as having no symptoms.

Patient follow-up data for major adverse cardiac events (MACEs) were collected with electronic medical record reviews and/or with standardized

telephone interviews. *MACE* was defined as cardiac death, nonfatal MI, unstable angina requiring hospitalization, and surgical treatment. *Cardiac death* was defined as death caused by acute MI, ventricular arrhythmias, or refractory heart failure. *Nonfatal MI* was defined on the basis of criteria of typical chest pain, elevated cardiac enzyme levels, and typical changes on the electrocardiogram. *Unstable angina* was defined according to the European Society of Cardiology guidelines as acute chest pain with or without presence of electrocardiographic abnormalities and cardiac biomarker levels within normal limits (13).

Cardiac CT

Contrast material-enhanced cardiac CT scans were obtained by using a 64-section multidetector CT scanner (Somatom Sensation 64; Siemens Medical Solutions, Forchheim, Germany). The cardiac CT protocol was as follows: In the absence of contraindications, patients with a heart rate higher than 65 beats per minute before examination received 50 mg of a beta-blocker (metoprolol tartrate, Betaloc; Yuhan, Seoul, Korea) and a 0.3-mg sublingual dose of nitroglycerin administered just before scanning initiation. A bolus of 60–80 mL iopamidol (Iopamiro 370; Bracco, Milan, Italy) was injected into an antecubital vein at a flow rate of 5 mL/sec, followed by a 50-mL saline-chasing bolus injected at a flow rate of 5 mL/sec. The start delay was defined by bolus tracking in the ascending aorta, and the scan start was automatically initiated 5 seconds after reaching the threshold level of 140 HU. Scanning was performed by using the following parameters: retrospective electrographically gated acquisitions, 100–120 kV, 600–800 mAs, depending on the patient's size, and a 64 × 0.6-mm section collimation. Scans were obtained from the tracheal bifurcation to the diaphragm. The field of view was adjusted according to the size of the heart. The cardiac CT scan was reconstructed by using a section thickness of 0.75 mm, an increment interval of 0.5 mm, and a medium-smooth convolution kernel of B30f.

Image Analysis

CT images were reviewed with software (AquarisNet Viewer V1.8.0.3; TeraRecon, San Mateo, Calif). Image data sets were analyzed by using multiplanar reformatted images (coronal, sagittal, vertical long-axis, short-axis, aortic valve, and pulmonary valve views), curved multiplanar reformatted thin-slab maximum intensity projection images, and volume-rendered images, in addition to the axial images. Two radiologists (H. J. L. and Y. J. K., with 3 and 6 years of experience in cardiac multidetector CT, respectively), who were both blinded to the patients' clinical findings, initially evaluated CT images independently, after which they reviewed all CT images again together (consensus reading).

AORL with an interarterial course was classified into two subtypes according to the location of the anomalous RCA ostium, as follows: (a) high interarterial course, with the RCA ostium located between the aorta and the pulmonary artery, so the proximal segment of the anomalous RCA travels between the aorta and pulmonary artery; and (b) low interarterial course, with the RCA ostium located between the aorta and the RVOT (ie, below the level of the pulmonary valve, with no segment between the aorta and pulmonary artery) (Fig 2).

Statistical Analysis

For interobserver agreement concerning the assignment of each patient to the appropriate interarterial course group, κ values were calculated by using software (SAS, version 9.1.3; SAS Institute, Cary, NC) to assess the proportion of interobserver agreement beyond that expected by chance (14).

For statistical analysis, we also used other software (SPSS, version 17.0 for Windows; SPSS, Chicago, Ill). We analyzed the differences in prevalence of baseline characteristics between the high interarterial course group and the low interarterial course group through the χ^2 contingency tables or the Fisher exact test. The χ^2 contingency tables or the Fisher exact test were also used to appraise the differences in prevalence

Figure 2

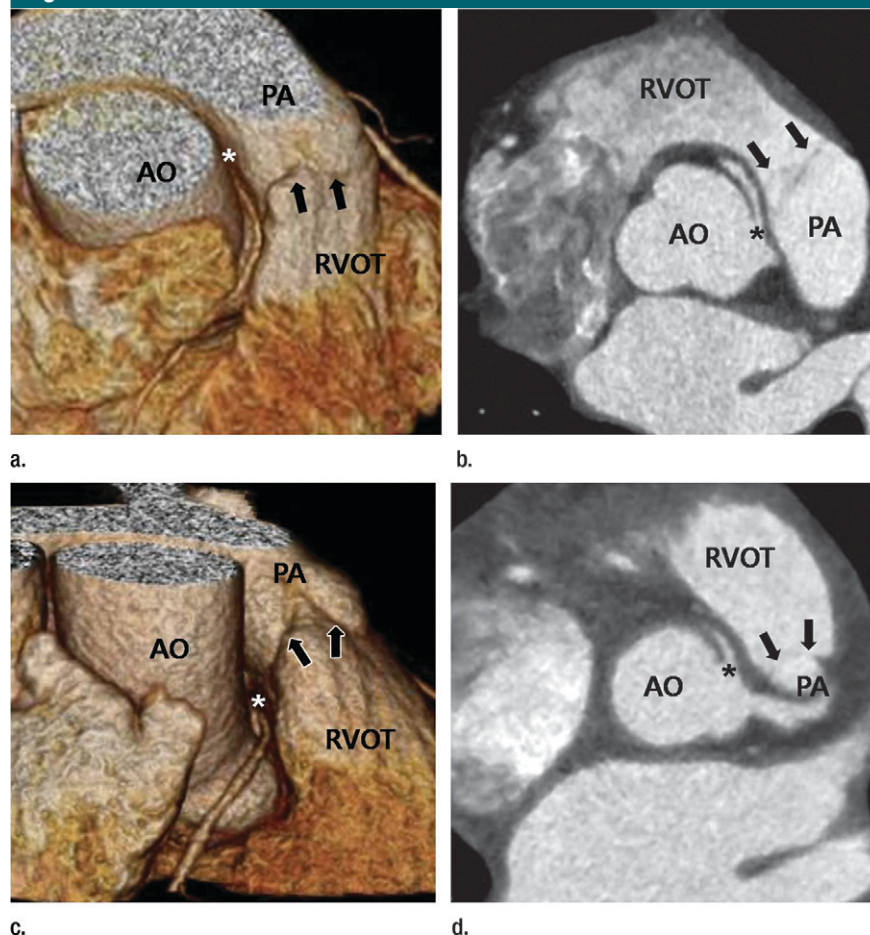


Figure 2: CT images in patients with high and low interarterial courses. (a, b) High interarterial course. (a) Volume-rendered three-dimensional image and (b) aortic valve multiplanar reformatted image in 54-year-old man demonstrate that the anomalous RCA ostium (*, also on c, d) from the left coronary sinus is located between the aorta (AO) and the pulmonary artery (PA) above the pulmonary valve (arrows, also on c, d). (c, d) Low interarterial course. (c) Volume-rendered 3D image and (d) aortic valve MPR image in 61-year-old woman show that the anomalous RCA ostium from the left coronary sinus is located between the aorta and the RVOT below the pulmonary valve.

of typical angina, MACE, and positive results of clinical tests between the two subtypes. Odds ratios and 95% confidence intervals for developing typical angina and MACE were determined through logistic regression to compare risks between patients in the high interarterial course group with those in the low interarterial course group. The independent Student *t* test was used to determine the differences in age between the high and the low interarterial course groups and between subjects with a MACE and subjects without a MACE. For all statistical tests, a

difference with a *P* value of less than .05 was significant.

Results

Prevalence of Coronary Artery Anomalies

The prevalence of each subtype is depicted in Figure E1 (online). In this study, we identified 390 (1.7%) of 22925 patients with coronary artery anomalies, and the most common coronary artery anomaly was AORL (31.8% [124 of 390]). All patients with AORL had an interarterial course.

Clinical Manifestations of Study Subjects according to Interarterial Course Group

Clinical Data	High Group (n = 53)	Low Group (n = 34)	PValue
Baseline characteristics			
Age (y)*	55.1 ± 13.2	57.4 ± 9.8	.379
Male sex†	36 (68)	15 (44)	.037
Female sex†	17 (32)	19 (56)	.037
Hypertension†	20 (38)	16 (47)	.389
Diabetes mellitus†	5 (9)	3 (9)	.923
Hyperlipidemia†	8 (15)	6 (18)	.752
Current smoker†	5 (9)	2 (6)	.552
Chest pain			
Typical angina†	23 (43)	2 (6)	.001
Atypical angina†	14 (26)	8 (24)	.763
Nonanginal chest pain†	2 (4)	6 (18)	.036
No chest pain†	14 (26)	18 (53)	.023
Syncope‡	2	3	
Dyspnea‡	1	1	
Palpitation‡	4	2	
No symptoms‡	7	12	
MACEs†	15 (28)	2 (6)	.012
Cardiac death‡	1	0	
Nonfatal MI§	3 (1)	0	
Unstable angina§	8 (4)	1 (1)	
Surgical treatment‡	3	1	

* Data are means ± standard deviations except where otherwise indicated.

† Data are numbers of patients, numbers in parentheses are percentages, and percentages were rounded, except where otherwise indicated.

‡ Data are numbers of patients except where otherwise indicated.

§ Data are numbers of patients, and numbers in parentheses are numbers of patients who underwent surgical treatment, except where otherwise indicated.

After excluding patients with combined cardiac disease (ie, coronary artery disease [$n = 30$], valvular heart disease [$n = 5$], coronary arterial fistula [$n = 1$], and hypertrophic cardiomyopathy [$n = 1$]), 87 patients (51 [59%] men, 36 [41%] women; mean age, 56.0 years; range, 20–80 years) were enrolled. The proximal portions of anomalous coronary arteries were well visualized on multidetector CT scans in all cases.

There were seven mismatched cases between the two observers, and an almost perfect agreement ($\kappa = 0.87$) was achieved between the two observers. Finally, after consensus reading took place, we found 53 cases with a high interarterial course and 34 cases with a low interarterial course.

Clinical Manifestations

The Table summarizes the baseline characteristics and clinical manifestations

of the patients. There was no significant difference in the prevalence of traditional risk factors for coronary artery disease. For patients with a high interarterial course, the prevalence of typical angina was 43% (23 of 53). Of patients with no chest pain in the high interarterial course group, four presented with palpitation, two with syncope, and one with dyspnea. Seven patients in the high interarterial course were definitely asymptomatic.

For patients with a low interarterial course, the prevalence of typical angina was 6% (two of 34). Of patients with no chest pain in the low interarterial course group, two had palpitation, three had syncope, and one had dyspnea. Twelve patients in the low interarterial course group definitely had no symptoms.

All patients with palpitation symptoms received a diagnosis of atrial

fibrillation, and none had palpitation after the treatment of atrial fibrillation with medication or radiofrequency ablation. Therefore, palpitation was considered to be unrelated to the coronary artery anomaly. Four of five patients with syncope received a diagnosis of vasovagal syncope by using the head-up tilting test. However, physicians found no disease that caused syncope in one patient with a low interarterial course. In this patient, syncope was considered to be related to the coronary artery anomaly. At follow-up, the patient had ventricular arrhythmia, and she underwent surgical treatment of the anomaly. Two patients complained of dyspnea, and in both, obstructive airway disease was diagnosed on the basis of spirometry results.

Major Adverse Cardiac Events

The median follow-up period for the study population was 921 days (interquartile range, 302–1419 days). In the high interarterial course group, cardiac death occurred in one patient; nonfatal MI occurred in three patients, and one of these patients underwent surgical treatment. The mean age of these four patients was 32.5 years. In eight high interarterial course group patients, unstable angina was diagnosed at presentation, and four of these patients underwent surgical treatment. In addition, three patients underwent surgical treatment for recurrent typical angina. Overall, the prevalence of MACE in the high interarterial course group was 28% (15 of 53).

No low interarterial course group patients had a sudden cardiac death or nonfatal MI. In one patient, unstable angina was diagnosed at presentation, and this patient underwent surgical treatment. In addition, as mentioned above in Clinical Manifestations, one low interarterial course group patient with recurrent syncope underwent surgical treatment. Thus, the prevalence of MACE in the low interarterial course group was 6% (two of 34). We evaluated the difference in age between subjects with a MACE and subjects without a MACE, and there was no significant difference ($P = .145$); in subjects with

a MACE, the mean age was 51.2 years \pm 15.4 (standard deviation) versus the mean age in subjects without a MACE of 57.2 years \pm 10.9.

Clinical Test Results

Table E1 (online) shows clinical test results. All patients (100%) underwent electrocardiography. ST-segment changes suggestive of inferior ischemia were visible in eight patients (15%) with a high interarterial course and in three (9%) patients with a low interarterial course. Sixty-five patients (75%) underwent echocardiography, and regional wall motion abnormality of the inferior wall of the left ventricle was noted in only two patients, both of whom were in the high interarterial course group. These subjects visited the emergency room and were diagnosed with nonfatal MI. Fifty-seven patients (66%) underwent a cardiac stress test, and in nine (16%), results were positive: seven (18%) of 38 were in the high interarterial course group and two (11%) of 19 were in the low interarterial course group. Although there was no significant difference in clinical test results between the two subtypes, we observed that ischemic change of the inferior left ventricle on the electrocardiogram and positive results of the cardiac stress test were more frequently noted in the high interarterial course subjects. However, the numbers of patients with positive results of electrocardiography and the cardiac stress test were generally low in patients with AORL with an interarterial course.

Conventional coronary angiography was performed in 29 patients (33%), and we confirmed that there was no significant coronary artery disease and AORL with an interarterial course in these patients. In six of 29 patients (21%), conventional coronary angiography was unsuccessful for the RCA because of catheterization failure at the anomalous RCA ostium.

Clinical Relevance

Figure 3 summarizes the clinical relevance. Significant differences were seen in the prevalence of typical angina between the two subtypes ($P = .001$, high [43%] vs low [6%]). The odds ratio for typical angina for patients with a high

Figure 3

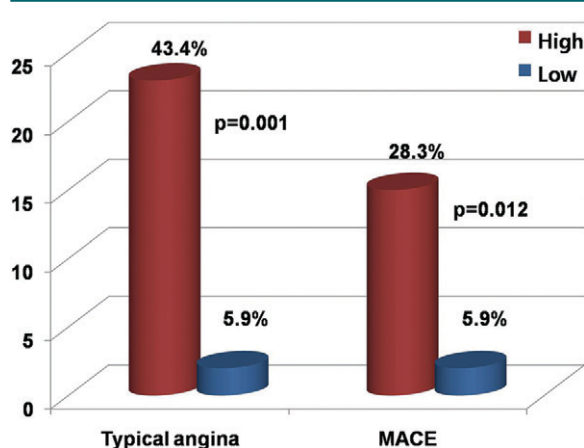


Figure 3: Clinical relevance. Prevalence of typical angina and MACEs between the high interarterial course group (*High*) and the low interarterial course group (*Low*). 43.4% = 43%, 5.9% = 6%, 28.3% = 28%.

interarterial course was 12.3 (95% confidence interval: 2.7, 56.6). Significant differences in the prevalence of MACE were also observed between the two subtypes ($P = .012$, high [28%] vs low [6%]). The odds ratio for MACE of patients with a high interarterial course was 6.3 (95% confidence interval: 1.3, 29.7).

Discussion

In this study, we observed a significantly higher prevalence of typical angina and MACE in the high interarterial course subjects.

The possible mechanisms of restricted coronary blood flow seen in interarterial courses are suggested to be the acute takeoff angle, the slitlike ostium, and compression of the intramural segment by the aortic valve commissure. Compression of the coronary artery between the aorta and the pulmonary artery is also a possible mechanism, particularly during exertion, and increased aortic wall distensibility causes additional compression of an already narrowed ostium during exercise (15–20).

Increased experience with this anomaly has made it clear that it is not always associated with sudden death (7), and many surviving patients with this anomaly have been found. The greatest challenge is determining its clinical relevance so that appropriate treatment can be initiated. However, investigators in several previous reports on risk stratification for this anomaly showed that cardiac

stress tests are unlikely to provide clinical evidence of myocardial ischemia, and premonitory cardiac symptoms are not uncommon shortly before sudden death (21,22). Moreover, researchers in a previous detailed autopsy study (23) demonstrated no relationship between clinical outcomes and anatomic variations, including the size and shape of the ostium, the length of the interarterial segment, and the takeoff angle. Lately, Lee et al (10) reported this anomaly at multidetector CT with clinical correlation, showing that the takeoff angles of anomalous RCAs with an interarterial course correlated with the relative narrowing of luminal diameters at the ostium at CT, but, in their study, symptoms were not correlated with the takeoff angle or relative luminal narrowing. So, on the basis of the data in previous literature, we applied a new classification of a high and a low interarterial course to this anomaly by using multidetector CT, and we observed the different clinical presentations between the two subtypes. The acute takeoff angle, slitlike ostium, and intramural segment of the AORL with an interarterial course could be predisposing factors to limiting coronary blood flow. In addition, a high course between the aorta and pulmonary artery could be a decisive factor in aggravating restriction of coronary blood flow, resulting in myocardial ischemia and infarction, especially during excessive exercise.

It is known that a coronary artery arising from the opposite sinus can take

any of four common courses: interarterial (between the aorta and the pulmonary artery), retroaortic, prepulmonic, or subpulmonic (septal) (24,25). The low interarterial course and the subpulmonic course are absolutely different, because the subpulmonic course passes through the infundibular septum (26), but the low interarterial course does not. However, to our knowledge, a subpulmonic course of AORL has not been reported in the literature (27,28). For the anomalous left coronary artery from the right coronary sinus, distinguishing “malignant” interarterial courses from “benign” subpulmonic courses is important because of the different clinical presentations (15,29). However, Torres et al (30) recently showed a mixed course between the septal and interarterial course by using CT, meaning the existence of a broader anatomic spectrum of anomalous left coronary artery that challenges the traditional dichotomous classification by using conventional coronary angiography. Likewise, we suggest subtypes of the AORL with an interarterial course that have different clinical relevance. We classified this anomaly into subtypes by using CT, because CT provides various multiplanar reconstructions that allow precise evaluation of the takeoff, course, and anatomic relationship of the anomalous coronary artery.

We compared the mean age between subjects with a MACE and subjects without a MACE, and there was no significant difference. However, the four patients in whom cardiac death or nonfatal MI occurred in the high interarterial course group were relatively young. We supposed that the aorta and pulmonary artery may be more distensible in the young and that greater distention can cause very severe compression of the interarterial course between the great vessels in the systolic phase, resulting in myocardial infarction. We suggest that physicians pay particular attention to younger patients who have AORL with a high interarterial course.

On the basis of our study results, we suggest some possible guidelines, as follows: For young patients (younger than 40 years old) with a high

interarterial course, we recommend surgical treatment even if the patients have no related symptoms. For patients older than 40 years old with a high interarterial course, we recommend surgical treatment for patients with related symptoms. And, for patients with a low interarterial course, we recommend close observation instead of surgical treatment, irrespective of age. But for the patients who have related symptoms, surgical treatment might be considered.

Our study limitations were as follows. First, although AORL with an interarterial course is known to be riskier in young adults, the age of our study population was relatively old (mean age, 56 years) because the study population included patients who had undergone cardiac CT. In other words, the patients with AORL with an interarterial course included in our study could be “survivors” of the anomaly. This factor might lead to an underestimation of the true risk of this anomaly. Second, we could not evaluate changes in vessel diameter throughout the cardiac cycle because we did not have raw CT data for all patients. Further study with multiphase reconstruction, including both the systolic and diastolic phases, might be needed. Third, anatomic information obtained from CT with the patient in the resting state might not properly be used to predict the risk of this anomaly because sudden cardiac death from this anomaly is related to severe exercise. Therefore, further mechanistic evaluation is necessary.

In conclusion, the prevalence of typical angina and a MACE was significantly higher in patients with a high interarterial course of AORL than it was in those with a low interarterial course. We think that our classification can be very useful for patient treatment in the near future, but further studies (ie, a prospective study, a study with other imaging modalities, a study with multiphase cardiac CT, and a long-term follow-up study) should be performed to definitely determine treatment guidelines with this new classification.

Acknowledgment: The authors thank D. S. Jang for his excellent support with medical illustration.

Disclosures of Potential Conflicts of Interest: H.J.L. No potential conflicts of interest to dis-

close. Y.J.H. No potential conflicts of interest to disclose. H.Y.K. No potential conflicts of interest to disclose. J.L. No potential conflicts of interest to disclose. J.H. No potential conflicts of interest to disclose. B.W.C. No potential conflicts of interest to disclose. H.J.C. No potential conflicts of interest to disclose. J.E.N. No potential conflicts of interest to disclose. K.O.C. No potential conflicts of interest to disclose. Y.J.K. No potential conflicts of interest to disclose.

References

1. Angelini P, Velasco JA, Flamm S. Coronary anomalies: incidence, pathophysiology, and clinical relevance. *Circulation* 2002;105(20):2449–2454.
2. Garg N, Tewari S, Kapoor A, Gupta DK, Sinha N. Primary congenital anomalies of the coronary arteries: a coronary arteriographic study. *Int J Cardiol* 2000;74(1):39–46.
3. Lee HJ, Kim YJ, Hur J, et al. Coronary artery anomalies: detection on coronary artery calcium scoring scan. *AJR Am J Roentgenol* 2010;194(5):W382–W387.
4. Cohen LS, Shaw LD. Fatal myocardial infarction in an 11 year old boy associated with a unique coronary artery anomaly. *Am J Cardiol* 1967;19(3):420–423.
5. Cheitlin MD, De Castro CM, McAllister HA. Sudden death as a complication of anomalous left coronary origin from the anterior sinus of Valsalva: a not-so-minor congenital anomaly. *Circulation* 1974;50(4):780–787.
6. Leberthson RR, Dinsmore RE, Bharati S, et al. Aberrant coronary artery origin from the aorta: diagnosis and clinical significance. *Circulation* 1974;50(4):774–779.
7. Gersony WM. Management of anomalous coronary artery from the contralateral coronary sinus. *J Am Coll Cardiol* 2007;50(21):2083–2084.
8. Shi H, Aschoff AJ, Brambs HJ, Hoffmann MH. Multislice CT imaging of anomalous coronary arteries. *Eur Radiol* 2004;14(12):2172–2181.
9. van Ooijen PM, Dorgelo J, Zijlstra F, Oudkerk M. Detection, visualization and evaluation of anomalous coronary anatomy on 16-slice multidetector-row CT. *Eur Radiol* 2004;14(12):2163–2171.
10. Lee BY, Song KS, Jung SE, et al. Anomalous right coronary artery originated from left coronary sinus with interarterial course: evaluation of the proximal segment on multidetector row computed tomography with clinical correlation. *J Comput Assist Tomogr* 2009;33(5):755–762.

11. Zhang LJ, Wu SY, Huang W, Zhou CS, Lu GM. Anomalous origin of the right coronary artery originating from the left coronary sinus of Valsalva with an interarterial course: diagnosis and dynamic evaluation using dual-source computed tomography. *J Comput Assist Tomogr* 2009;33(3):348–353.
12. Gibbons RJ, Balady GJ, Beasley JW, et al. ACC/AHA guidelines for exercise testing: executive summary. A report of the American College of Cardiology/American Heart Association Task Force on Practice Guidelines (Committee on Exercise Testing). *Circulation* 1997;96(1):345–354.
13. Rapezzi C, Biagini E, Branzi A. Guidelines for the diagnosis and treatment of non-ST-segment elevation acute coronary syndromes: the task force for the diagnosis and treatment of non-ST-segment elevation acute coronary syndromes of the European Society of Cardiology. *Eur Heart J* 2008;29(2):277–278.
14. Barnhart HX, Williamson JM. Weighted least-squares approach for comparing correlated kappa. *Biometrics* 2002;58(4):1012–1019.
15. Roberts WC, Siegel RJ, Zipes DP. Origin of the right coronary artery from the left sinus of Valsalva and its functional consequences: analysis of 10 necropsy patients. *Am J Cardiol* 1982;49(4):863–868.
16. Virmani R, Chun PK, Goldstein RE, Robinowitz M, McAllister HA. Acute take-offs of the coronary arteries along the aortic wall and congenital coronary ostial valve-like ridges: association with sudden death. *J Am Coll Cardiol* 1984;3(3):766–771.
17. Kragel AH, Roberts WC. Anomalous origin of either the right or left main coronary artery from the aorta with subsequent coursing between aorta and pulmonary trunk: analysis of 32 necropsy cases. *Am J Cardiol* 1988;62(10 pt 1):771–777.
18. Taylor AJ, Rogan KM, Virmani R. Sudden cardiac death associated with isolated congenital coronary artery anomalies. *J Am Coll Cardiol* 1992;20(3):640–647.
19. Frescura C, Basso C, Thiene G, et al. Anomalous origin of coronary arteries and risk of sudden death: a study based on an autopsy population of congenital heart disease. *Hum Pathol* 1998;29(7):689–695.
20. Lee BY. Anomalous right coronary artery from the left coronary sinus with an interarterial course: is it really dangerous? *Korean Circ J* 2009;39(5):175–179.
21. Basso C, Maron BJ, Corrado D, Thiene G. Clinical profile of congenital coronary artery anomalies with origin from the wrong aortic sinus leading to sudden death in young competitive athletes. *J Am Coll Cardiol* 2000;35(6):1493–1501.
22. Osaki M, McCrindle BW, Van Arsdel G, Dipchand AI. Anomalous origin of a coronary artery from the opposite sinus of Valsalva with an interarterial course: clinical profile and approach to management in the pediatric population. *Pediatr Cardiol* 2008;29(1):24–30.
23. Taylor AJ, Byers JP, Cheitlin MD, Virmani R. Anomalous right or left coronary artery from the contralateral coronary sinus: “high-risk” abnormalities in the initial coronary artery course and heterogeneous clinical outcomes. *Am Heart J* 1997;133(4):428–435.
24. Ropers D, Gehling G, Pohle K, et al. Images in cardiovascular medicine: anomalous course of the left main or left anterior descending coronary artery originating from the right sinus of Valsalva—identification of four common variations by electron beam tomography. *Circulation* 2002;105(6):e42–e43.
25. Kim SY, Seo JB, Do KH, et al. Coronary artery anomalies: classification and ECG-gated multi-detector row CT findings with angiographic correlation. *RadioGraphics* 2006;26(2):317–333; discussion 333–334.
26. Nath H, Singh SP, Lloyd SG. CT distinction of interarterial and intraseptal courses of anomalous left coronary artery arising from inappropriate aortic sinus. *AJR Am J Roentgenol* 2010;194(4):W351–W352.
27. Ayalp R, Mavi A, Serçelik A, Batyraliev T, Gümüşburun E. Frequency in the anomalous origin of the right coronary artery with angiography in a Turkish population. *Int J Cardiol* 2002;82(3):253–257.
28. Yamanaka O, Hobbs RE. Coronary artery anomalies in 126,595 patients undergoing coronary arteriography. *Cathet Cardiovasc Diagn* 1990;21(1):28–40.
29. Selig MB, Jafari N. Anomalous origin of the left main coronary artery from the right coronary artery ostium-interarterial subtype: angiographic definition and surgical treatment. *Cathet Cardiovasc Diagn* 1994;31(1):41–47.
30. Torres FS, Nguyen ET, Dennie CJ, et al. Role of MDCT coronary angiography in the evaluation of septal vs interarterial course of anomalous left coronary arteries. *J Cardiovasc Comput Tomogr* 2010;4(4):246–254.